

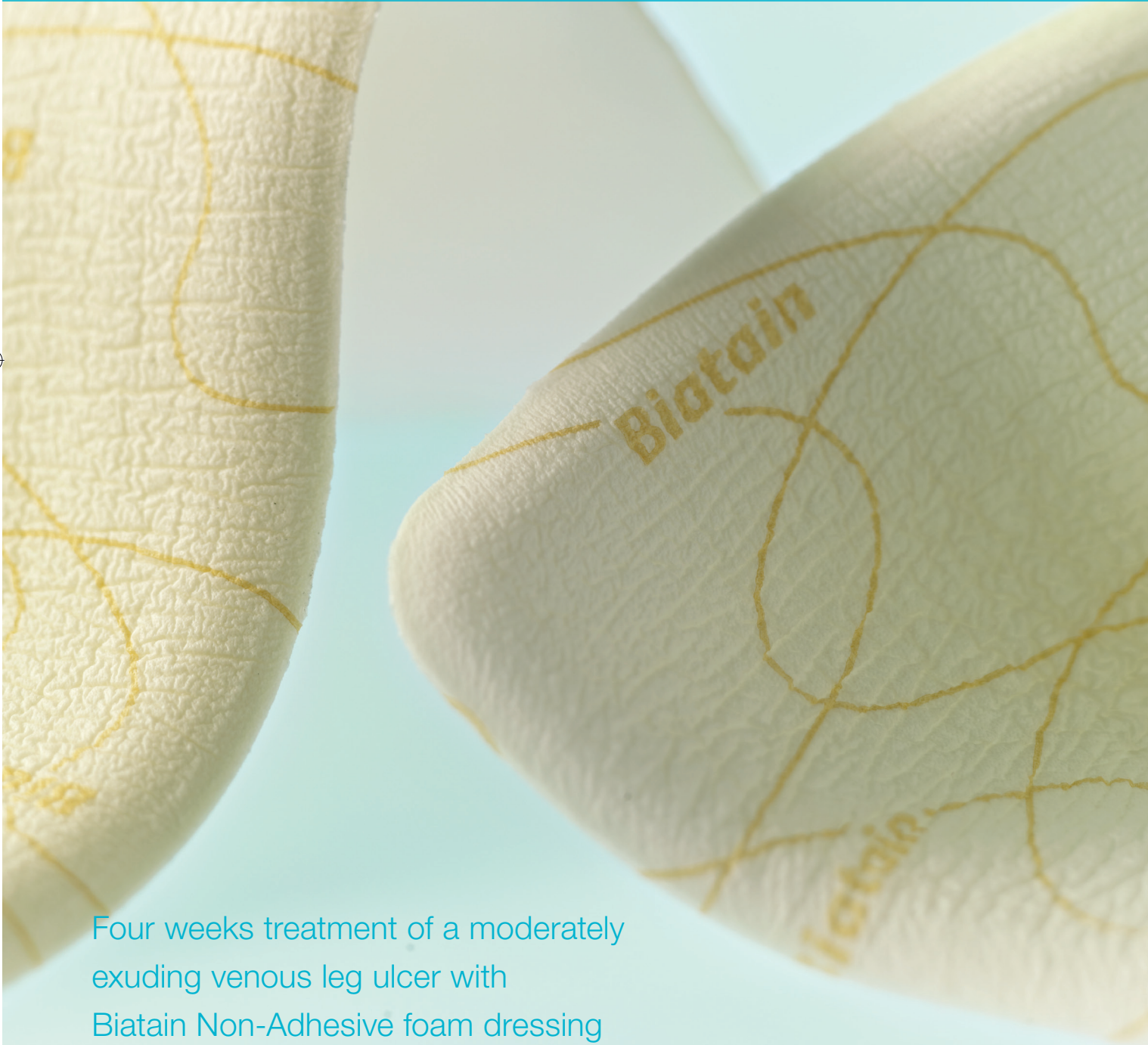

Biatain[®]



Biatain[®] Non-Adhesive

Case study



Four weeks treatment of a moderately exuding venous leg ulcer with Biatain Non-Adhesive foam dressing

Biatain[®] – the simple choice



Case study

Four weeks treatment of a moderately exuding venous leg ulcer with Biatain® Non-Adhesive foam dressing

Authors: Bech-Thomsen N. & Jensen N. Dermatology Clinic, Naestved, Denmark

Introduction

This report describes four weeks treatment with Biatain Non-Adhesive in combination with compression therapy, on a patient suffering from a moderately exuding, venous leg ulcer.

Leg ulcers are commonly a long-term disease, with significant costs for the patient as well as the healthcare system. Leg ulcers often have a negative impact on the patients quality of life due to pain, reduced mobility and social isolation¹. The prevalence of leg ulcers rises with increasing age, and 3-5% of elderly people suffer from chronic leg ulcerations^{2,3}.

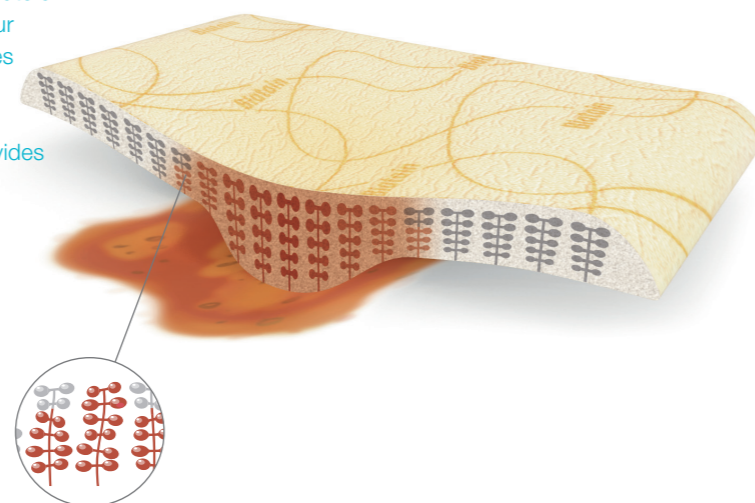
Use of absorbent foam dressings is accepted as best practice by advanced wound care practitioners⁴. Foam dressings have high absorption capacity and provide better exudate handling, less maceration and minimal leakage⁵.

Biatain foam dressings have superior absorption, are soft and conformable and are providing an optimal moist environment for faster wound healing.

Biatain foam dressings are protected with semi-permeable film backings that are waterproof and provide bacterial barriers. Biatain Non-Adhesive are suitable on fragile skin.

Biatain Non-Adhesive provides a superior absorption and optimal moist wound healing environment. Exudate is absorbed locally into the foam pad with minimal lateral dispersal, thus preventing maceration. Water vapour evaporates through the backing film, which provides bacterial barrier and withstands strikethrough of exudate. The combination of the soft foam and the bevelled edges minimises pressure marks and provides sealed edges, reducing the risk of leakage.

Unique 3D polymer structure



Wound Progress

After just one week the ulcer area was reduced by 41%. After two weeks of treatment the ulcer area was reduced by 73%. The ulcer now consisted of 100% healthy granulation tissue (Figure 2). At the end of the treatment the wound bed consisted of 100% healthy granulation tissue and the ulcer area was only 0.3 cm² (Figure 3), corresponding to a 95% reduction in ulcer area (Figure 4).

Dressing performance

Biatain Non-Adhesive supported fast wound healing, resulting in an almost complete wound healing within the four weeks of treatment. Although compression therapy was applied, exudate handling was rated 'excellent' (1 on a 1-5 point scale), causing no leakage or maceration during the entire treatment. Pressure marks were rated as 'vague imprints' at week one, and as 'none or very vague imprints' the rest of the treatment period. The patient found the dressing comfortable to wear, and experienced no pain at dressing changes. No adverse events were recorded.

Conclusion

During the four weeks treatment period:

- Biatain Non-Adhesive demonstrated remarkable reduction in ulcer size
- Biatain Non-Adhesive caused no leakage or maceration, even under compression therapy
- Biatain Non-Adhesive minimised pressure marks
- Biatain Non-Adhesive was comfortable and easy to use

Relative ulcer size reduction

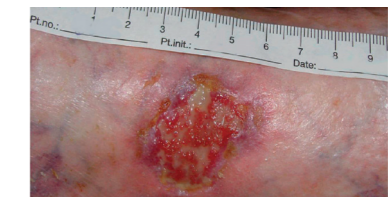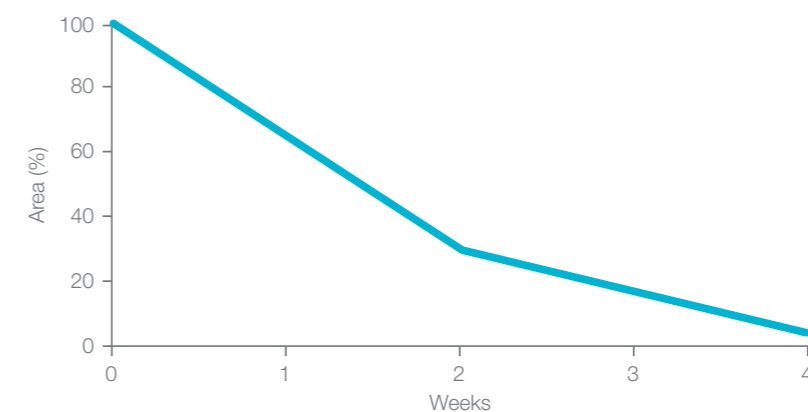


Figure 1. The ulcer at inclusion after cleansing.

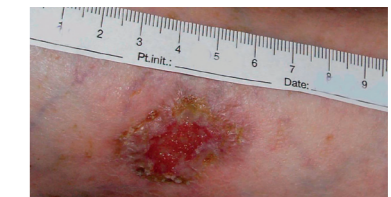

Figure 2. Ulcer area was reduced by 73% after two weeks treatment.

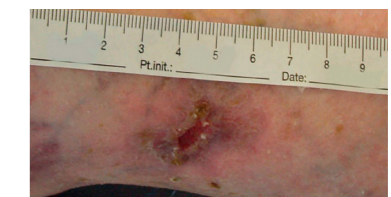


Figure 3. After four weeks treatment the ulcer area was reduced by 95%.

Figure 4. Treatment with Biatain Non-Adhesive resulted in improved wound bed conditions combined with dramatically reduction in ulcer size.

Medical history

The patient is an 85 years old woman suffering from a venous leg ulcer on the lateral part of her lower left leg. The skin on her leg is fragile. The ulcer had persisted for five months at inclusion. Prior to inclusion, the ulcer had been treated with alginate dressings and compression therapy for ten weeks. Ulcer healing was delayed compared to normally expected healing rate. On the 3rd of April the patient began treatment with Biatain Non-Adhesive. The ulcer area was 4.9 cm². The ulcer contained 20% fibrinous tissue and 80% healthy granulation tissue. Figure 1 shows the ulcer at inclusion after cleansing. During the four weeks treatment period a long stretch compression bandages were applied.

Biatain® Non-Adhesive

Superior absorption – for wounds with extra fragile skin

Biatain

Non-Adhesive Foam Dressings



	Item no.	National code
10x10	3410	
10x20	3412	
15x15	3413	
20x20	3416	
5x7	6105	
5x8 cavity	3451	

Product ordering information For product availability please contact your local Coloplast office or distributor. Find contact information at www.coloplast.com

References: 1. Lindholm C et al. Acta Dermato-Venereologica 1993;73(6):440-443. 2. Gottrup F & Karlsmark T. Ugeskrift for læger 2000;167(7):911-914
3. Philips T et al. Journal of the American Academy of Dermatology 1994;31(1):49-53. 4. Kunimoto B et al: Best Practices for the Prevention and Treatment of Venous Leg Ulcers; Ostomy/wound Management, 2001;47(2):34-50 5. Thomas S et al. Journal of Wound Care 1997;6(8):383-386.

Ostomy Care
Urology & Continence Care
Wound & Skin Care

Coloplast develops products and services that make life easier for people with very personal and private medical conditions. Working closely with the people who use our products, we create solutions that are sensitive to their special needs. We call this intimate healthcare. Our business includes ostomy care, urology and continence care and wound and skin care. We operate globally and employ more than 7,000 people.

The Coloplast logo is a registered trademark of Coloplast A/S. © 2012-02.
All rights reserved Coloplast A/S, 3050 Humlebæk, Denmark.



Coloplast A/S
Holtedam 1
3050 Humlebæk
Denmark

www.coloplast.com